

RESEARCH ARTICLE

**THE RELATIONSHIP BETWEEN AGGRAVATED *ALLIUM SATIVUM* CONSUMPTION AND CYTOTOXICITY OF THE PREGNANT RATS WITH SUBSEQUENT EMBRYONIC GROWTH RETARDATION**

**Zeinab Kamal<sup>1\*</sup>; Zeinab Al-Amgad<sup>2</sup>; and Seham A. Mobarak<sup>1</sup>**

<sup>1</sup>Zoology Department, Faculty of Science, South Valley University, Qena, Egypt

<sup>2</sup>General Authority for Veterinary Services, Qena Veterinary Directorate, Qena, Egypt

**ABSTRACT**

**Article History:**

Received: 19 June 2023

Accepted: 30 July 2023

Published Online:

14 August 2023

**Keywords:**

*Allium sativum*

Fetus

Liver toxicity

Pregnant rats

Spleen damage

**\*Correspondence:**

Zeinab Kamal

Zoology Department

Faculty of Science

South Valley University

Qena, Egypt

E-mail:

[zinabmostafa@sci.svu.edu.eg](mailto:zinabmostafa@sci.svu.edu.eg)

Herbs and spices are frequently used for culinary and medicinal intention. One of the herbs that is extremely consumed in dietary and therapeutic object is garlic (*Allium sativum*) with special concern in urban countries. Nevertheless, various controversies persist about the advantageous or the toxic effects of garlic depending on administration mode and garlic dosage. Twenty female pregnant rats were evenly distributed into two groups, control and treated groups (n = 10). In the treated group, each pregnant rat received orally 2 g/kg body weight of garlic aqueous extract on day 6 of pregnancy. On the 20<sup>th</sup> day of gestation, morphological, biochemical, and histological investigations were performed to appreciate the cellular abnormalities in the maternal ovary and damage in liver and spleen of both pregnant rats and their embryos. The results showed that garlic extract at a dose of 2 g/kg body weight produced an intense cytotoxic effect on the liver and splenic tissues of the pregnant females and their progeny and obviously-detected congenital malformations in the progression of the fetuses. A significant elevation in the aspartate aminotransferase activity and the levels of the total proteins, interleukin-6, malondialdehyde, and nitric oxide; while a significant reduction in the activities of superoxide dismutase and glutathione peroxidase were detected in the garlic-treated group when compared with the control group. In conclusion, garlic disrupts significantly the liver functions and immunity of the pregnant rats. Moreover, congenital deformations were detected in the fetuses of the garlic-treated pregnant rats.

**INTRODUCTION**

Phytochemicals have been isolated from spices, fruits, vegetables, beverages, and other known sources<sup>[1]</sup>. Species such as garlic (*Allium sativum*) is qualified as broad-spectrum antimicrobial agent<sup>[2]</sup>. Various commercially garlic preparations are available in form of spices, beverage, and capsulated drugs including herbal

therapy. Several health problems including constipation, esophageal cancer, fever, asthma, and hypertension have been managed by traditional medicinal plants<sup>[3]</sup>. Natural remedies have been an integral part of the ancient classical medicine systems, such as Egyptian, Chinese, and Ayurvedic<sup>[4]</sup>.

Garlic is a widespread medicinal plant afforded beneficial health effects like antioxidant, antidiabetic, or hypolipidemic. However, various controversies persist about the beneficial or toxic effects of garlic according to its mode of administration. Heavy garlic consumption is pro-oxidant as altering lipid peroxidation levels reflected by higher levels of malondialdehyde (MDA) and  $H_2O_2$ , in turn of a decrease in free iron deposition, and activities of peroxidase, catalase, and superoxide dismutase<sup>[5]</sup>. The medicinal value of *Allium sativum* has been extendedly described. Additionally, the widespread advantages of garlic for its medicinal activities has accompanied by its increase demand thus justifying the need to study the potential toxicity of garlic extracts on vital organs of the body. Nevertheless, little scientific investigations for the potential toxicity of garlic on vital organs are available<sup>[6]</sup>. Excess doses of garlic induced toxicity, comprising anemia<sup>[7]</sup>. Administration of high doses of garlic in powder preparation caused considerable liver injury in rats<sup>[8]</sup>, which was not found at lower doses. Approximately 1000 mg/kg of garlic resulted in hepatic necrosis<sup>[9]</sup>. Orally ingested fish of 2 g/kg of *Allium sativum* juice showed decreased serum alkaline phosphatase (ALP) activity with non-significant changes in serum aspartate aminotransferase (ASAT) and alanine aminotransferase (ALAT) activities. In addition, liver architecture suffered from glycogen depletion, hypertrophy, and degeneration of the hepatocytes, in addition to congestion and dilatation of the blood vessels in garlic-treated fish<sup>[10]</sup>.

Garlic (*Allium sativum*) has potential to modulate immune response of inflammatory cytokines and proliferation of human lymphocytes<sup>[11]</sup>. Spleen is a key organ for iron metabolism and erythrocyte homeostasis. As well, it is the main filter for blood-borne pathogens and antigens for regulation the immune response<sup>[12]</sup>. It has been shown that intragastric infusion of a high dose of raw garlic resulted in gastrointestinal injury includes ulcers and bleeding, besides its

damaging effect on splenic tissues that was evident on the splenic pulps, lymphoid follicles, and trabecular tissues<sup>[13]</sup>. Excessive consumption of garlic extract displayed hyperplasia of spleen pulps with perivascular mononuclear cell infiltration<sup>[14]</sup>.

Eventually, the irrational consumption of herbals during pregnancy is responsible for unfriendly maternal and fetal consequence with premature birth<sup>[15]</sup>. Notably, the long-term consumption of garlic adversely influenced the health status of the offspring with consequent locomotors behavioral activities. Moreover, prolonged administration of garlic by adult female rats prior and during pregnancy altered the fecundity of their offspring and the sex rate of their male and female offspring<sup>[16]</sup>. Thence, the current study was designed to assess the adverse effect of unbelievably consumption of garlic aqueous extract on the pregnant female and their offspring.

## MATERIAL AND METHODS

### Garlic (*Allium sativum*) collection and preparation

*Allium sativum* L. Sids 40, Family: Amaryllidaceae J.St.-Hil. cloves of the bulb-stem used in this study were brought from a local market belonging to Qena governorate (Egypt); they were identified and authenticated by Dr. Hussein, N. R. A. (Botany Department, Faculty of Science, South Valley University). Garlic extract was intended according to experimental procedure as previously reported<sup>[17]</sup> using a warm water technique. Accordingly, garlic cloves in a dose of 200 g were preceded peeling and mincing, followed by warming at 45° C for 15 minutes after addition of 150 mL of distilled water; ultimately filtrates were ready for fresh uses.

### Identification of constituents in garlic aqueous extract using GC-MS

The garlic extract compositions identified using gas chromatography mass spectrometry (GC-MS) depending on comparison of retention times (RT) and mass spectra<sup>[18]</sup>.

GC-MS/MS analysis was conducted in Nawah Scientific (Cairo, Egypt).

### **Experimental animals**

In this a descriptive experimental study, 20 female pregnant rats within average body weights 200-220 g were recruited. They were purchased from the laboratory animal house belonging to Sohag University (Sohag Governorate, Egypt). Animals were housed in special cages under sanitary atmospheric conditions for a period of two weeks to be acclimatized. The animals supplied healthy feeding, and clean drinking.

### **Experimental design**

The animal care was performed based on the guidelines of the Experimental Animal Care of the Faculty of Science, South Valley University (Qena, Egypt) and the experimental design of the current study was approved (Approval number: 019/11/22). In this experiment, twenty pregnant female albino rats were equally divided into two groups: group "1" (control; n=10), each female pregnant rats received orally distilled water; group "2" (treated group, n=10), each female pregnant rat was orally consumed 1.0 mL/day garlic extract. Distilled water and garlic extract were supplied to the control group and the treated group, respectively, on the 6<sup>th</sup> day of pregnancy, where organs of the embryos are formed in such period. On the 20<sup>th</sup> day of pregnancy, all pregnant female rats of the experimental groups were anesthetized and tissue samples from liver, spleen, and ovary of the pregnant mother, as well as embryonic samples from liver and spleen were dissected and fixed in solution neutral buffer for further histological analysis. Uterus holding embryos was primarily checked accurately to identify live, dead, or deformed embryos; and worthily photographed tissues of embryos were imaged. Pregnant mothers were subjected for a daily surveillance and oversight during the exposure.

### **Biochemical analysis**

The colorimetric methods proved by Reitman and Frankel<sup>[19]</sup>, Gornall *et al.*<sup>[20]</sup>, Ohkawa *et al.*<sup>[21]</sup>, and Rider and Mellon<sup>[22]</sup>

were devoted for the assay of serum aminotransferase activities, and proteins, MDA, and nitric oxide levels, respectively, by using Biodiagnostic kits (Giza, Egypt). The ELISA kit supplied by Wuhan Boster Biological Technology Co., Ltd. (Wuhan, China) was used for assessment of rat interleukin(IL)-6. The colorimetric methods proceeded by Nishikimi *et al.*<sup>[23]</sup> and Paglia and Valentine<sup>[24]</sup> were used for the determination of serum activities of superoxide dismutase (SOD) and glutathione peroxidase (GPx), respectively.

### **Histological investigations**

Following necropsy, specimens were gathered from the maternal and fetal tissues for macroscopic and microscopic examinations. The procedure of histopathology was carried out as expressed by Carleton *et al.*<sup>[25]</sup>. Meanwhile, maternal biopsies from liver, spleen, and ovary, as well as fetal biopsies of liver and spleen were consecutively processed in an ascending series of ethanol. Subsequent paraffin sections were stained with Harries hematoxylin and eosin (H&E.) and with Masson's trichrome for microscopic readings.

### **Statistical analysis**

Statistical analysis was carried out *via* Statistical Package for Social Sciences (SPSS) program by T-Test. The results were mentioned in form of mean  $\pm$  standard deviation. The mean was significantly changed when  $P < 0.05$ .

## **RESULTS**

### **Characterization of chemical constituents of garlic aqueous extract using GC-MS**

The GC-MS chromatogram results (Table 1) showed the bioactive components found in garlic aqueous extract.

### **Morphological alterations induced by garlic aqueous extract in pregnant rats and its fetuses**

The total body weights of the fetuses of the pregnant rats were significantly decreased ( $P < 0.05$ ) among garlic consuming rats

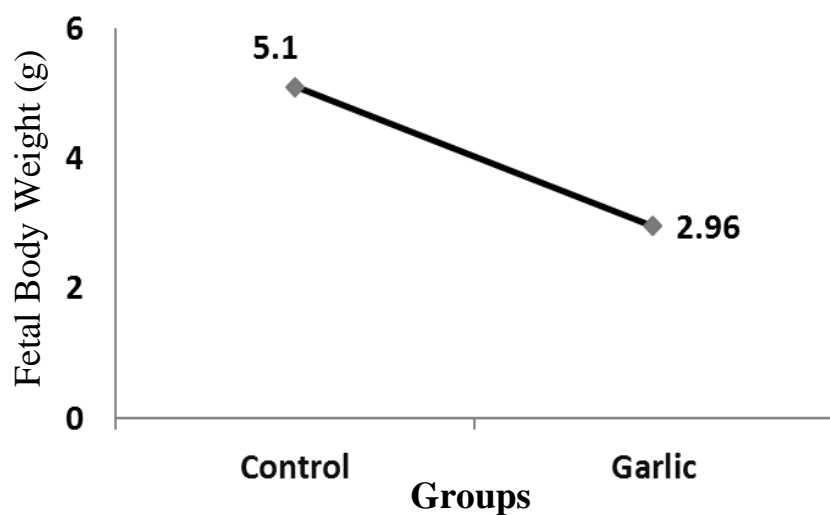
**Table 1:** Phytochemical analysis of garlic aqueous extract by GC–MS.

Number	Compound Name	Retention time (min)	Area (%)	Molecular Weight (g/mol)	Molecular Formula
1	Cyclopentanedicarboxylic acid	6.53	3.41	242	C <sub>13</sub> H <sub>22</sub> O <sub>4</sub>
2	Isopropenyl-2-methylcyclohexanol	9.73	0.73	157	C <sub>10</sub> H <sub>15</sub> D <sub>3</sub> O
3	Trisulfide, di-2-propenyl	11.25	0.99	178	C <sub>6</sub> H <sub>10</sub> S <sub>3</sub>
4	Tetradecanoic acid	22.41	0.69	228	C <sub>14</sub> H <sub>28</sub> O <sub>2</sub>
5	9-Hexadecenoic acid	25.93	0.70	254	C <sub>16</sub> H <sub>30</sub> O <sub>2</sub>
6	Linoelaidic acid	29.43	23.35	308	C <sub>20</sub> H <sub>36</sub> O <sub>2</sub>
7	Oleic acid	29.60	20.39	282	C <sub>18</sub> H <sub>34</sub> O <sub>2</sub>
8	Hi-oleic safflower Oil	29.91	0.69	450	C <sub>21</sub> H <sub>22</sub> O <sub>11</sub>
9	Octadecanoic acid	30.07	3.31	284	C <sub>18</sub> H <sub>36</sub> O <sub>2</sub>
10	13-Heptadecyn-1-ol	30.92	1.27	252	C <sub>17</sub> H <sub>32</sub> O
11	Glycidyl oleate	32.08	0.67	338	C <sub>21</sub> H <sub>38</sub> O <sub>3</sub>
12	6,9,12-Octadecatrienoic acid, methyl ester	33.99	0.66	292	C <sub>19</sub> H <sub>32</sub> O <sub>2</sub>
13	Linolenic acid, 2-hydroxy-1-(hydroxymethyl) ethylester (Z,Z,Z)-	34.74	0.48	352	C <sub>21</sub> H <sub>36</sub> O <sub>4</sub>
14	Hexadecanoic acid, 1 (hydroxymethyl)-1,2-ethanediyl ester	35.31	3.04	568	C <sub>35</sub> H <sub>68</sub> O <sub>5</sub>
15	1,2-Benzenedicarboxylic acid	35.86	2.24	390	C <sub>24</sub> H <sub>38</sub> O <sub>4</sub>
16	9,12-Octadecadienoic acid (Z,Z)-,2-hydroxy-1-(hydroxymethyl) ethyl ester	37.83	3.40	354	C <sub>21</sub> H <sub>38</sub> O <sub>4</sub>
17	9-Octadecenoic acid (Z)-,2 hydroxy-1-(hydroxymethyl) ethyl ester	37.94	4.70	356	C <sub>21</sub> H <sub>40</sub> O <sub>4</sub>
18	1-Heptatriacotanol	41.59	1.08	536	C <sub>37</sub> H <sub>76</sub> O

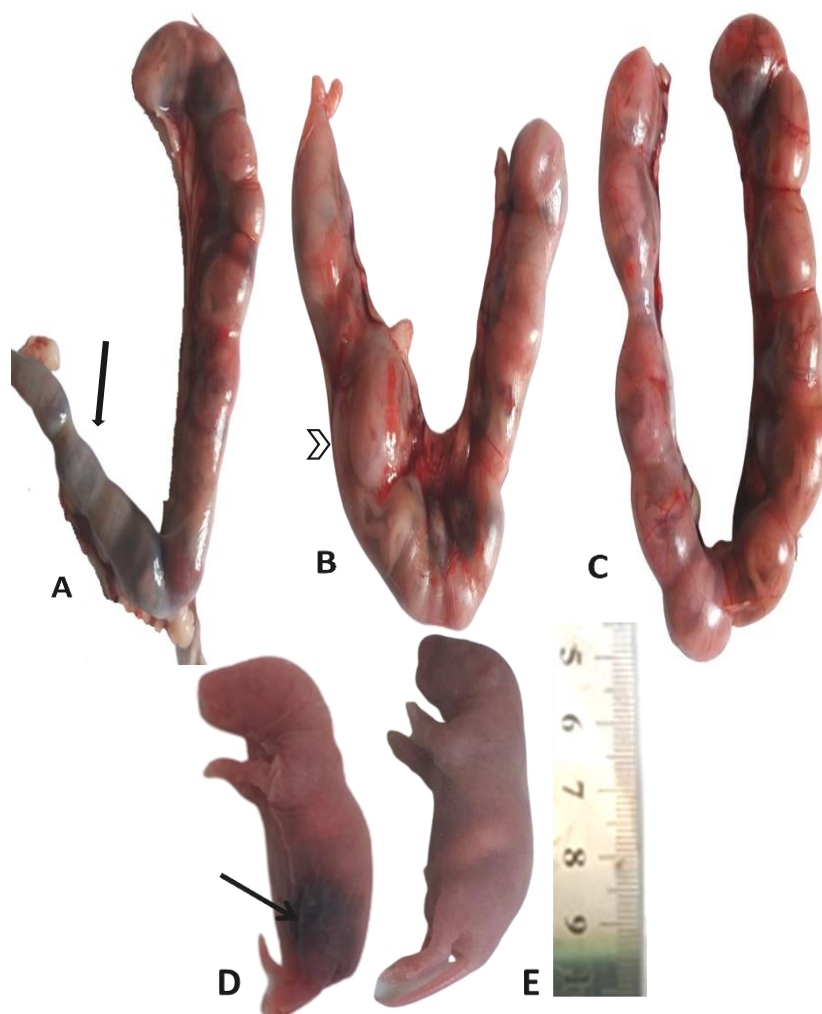
(2.96±0.15 g) in comparison with the control ones (5.1±0.35 g), as shown in Figure "1". On the 20<sup>th</sup> days post pregnancy, the uterus in the control group displayed symmetrical distribution and equal organization of embryos as described in (Figure 2C). However, in garlic extract treated group, uterus exhibited aggravated sites of hemorrhagic implantation that explicated early absorbed fetus (Figure 2A) and uterus demonstrated unequal organization of fetuses (Figure 2B). Embryos of control group of 10 pregnant female albino rats were all alive and manifested vital and healthy conditions (Figure 2E). However, in garlic-treated

group, the average live embryo was 40%, and the other abnormal fetus seemed of congenital developmental malformations as superficial hematoma with subcutaneous blood clots (Figure 2D).

From gross necropsy, liver and splenic tissues of the control pregnant female and their embryos sound healthy within normal sizes and texture. Otherwise, those of garlic-treated rats were suffered from diffuse areas of congestion. Besides this, ovarian tissues of the control pregnant rats appeared intact; while, ovaries in garlic-treated rats were seemed to be darkish red in color and expressed scattered congested foci.



**Figure 1:** Effect of garlic aqueous extract on the fetal body weight.



**Figure 2:** Photograph of uterus and fetuses on gestational day 20 of garlic-treated pregnant rats (A, B and D) and control pregnant rats (C and E). (A) Absorbed fetuses (black arrow) replaced by large hemorrhagic implantation. (B) Unequal distribution of fetuses (arrow head). (C) Normal and symmetrical distribution inside uterus. (E) Normal fetus with healthy shape. (D) Some growth retardation as superficial hematoma (black arrow).

**Effect of garlic aqueous extract on serum biochemicals**

Our results displayed that the pregnant rats treated with garlic extract had significant increases in the activity of serum ASAT and the levels of serum total protein, IL-6, MDA,

and nitric oxide ( $P < 0.05$ ) as compared with control group (Table 2). On the other hand, the pregnant rats treated with garlic extract had significant increases in the activities of serum SOD and GPx as compared with control group (Table 2).

**Table 2:** Effect of aqueous extract of garlic on serum biochemical parameters (mean  $\pm$  standard deviation).

	Control group	Garlic group
ASAT activity (IU/L)	118.0 $\pm$ 3.0	127.0 $\pm$ 2.0*
ALAT activity (IU/L)	15.0 $\pm$ 1.0	17.0 $\pm$ 1.0
Total protein (g/dL)	2.50 $\pm$ 0.45	5.50 $\pm$ 0.62*
IL-6 (pg/L)	0.41 $\pm$ 0.04	0.92 $\pm$ 0.05*
MDA (nmol/g)	2.0 $\pm$ 1.0	5.3 $\pm$ 1.5*
Nitric oxide (nmol/g)	231.0 $\pm$ 2.0	315.0 $\pm$ 3.6*
SOD (U/mL)	445.0 $\pm$ 2.6	425.0 $\pm$ 3.0*
GPx (U/mL)	1342.0 $\pm$ 4.0	1250.0 $\pm$ 3.0*

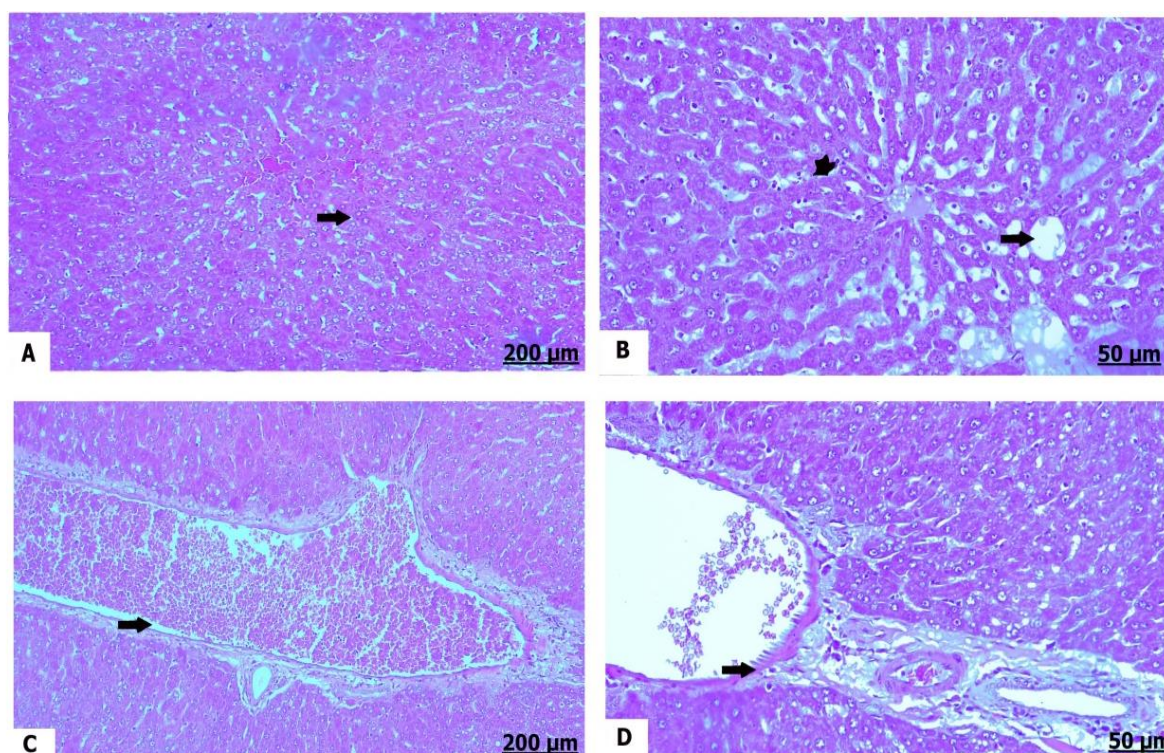
\* $P < 0.05$  compared with the control group.

**Histopathological alterations induced by garlic aqueous extract in pregnant rats and its fetuses**

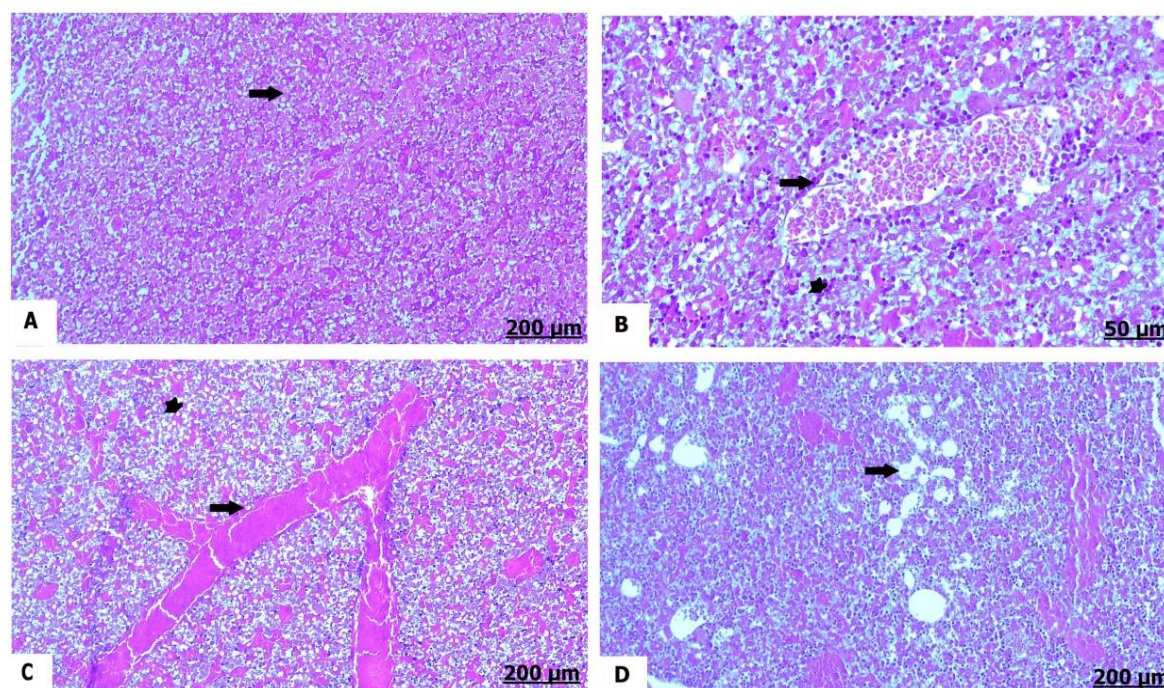
Histological examinations of liver of the control pregnant rats exhibited normal histological architecture of the hepatic tissues, whereas the hepatic cords were arranged in a good manner (Figure 3A). A result of garlic treatment; liver tissues of pregnant rats showed fatty degeneration with fat vacuoles infiltration and pronounced lymphocytes infiltrates (Figure 3B). Moreover, hepatic vasculatures were intensely congested and full of stagnant blood, as well perivascular infiltration (Figure 3C and D). Histological examinations of liver of control embryos showed intact hepatic cords (Figure 4A). Contrariwise, variable degrees of blood vessels congestion were detected in liver of garlic-exposed embryos, besides cells infiltrate (Figure 4B and C). Additionally, cytoplasmic fatty infiltration was observed (Figure 4D).

Histological examinations of spleen of the control pregnant rats demonstrated normally appearing splenic pulps (Figure 5A). Spleen

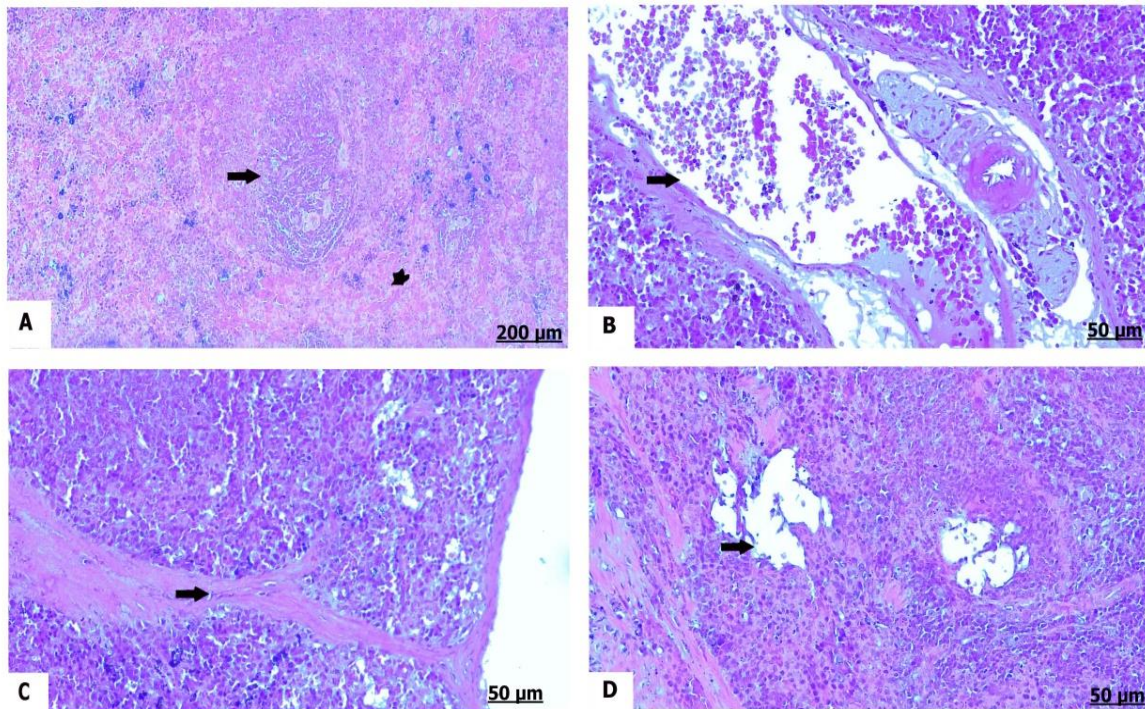
of garlic-treated group subserved remarkable degree of congestion of the splenic vessels (Figure 5B). Similarly, splenic trabeculae were protruded (Figure 5C). In addition, the splenic pulps suffered from atrophy with vacuolation (Figure 5D). Histological examinations of spleen of the control fetal tissues signified healthy white and red pulps (Figure 6A). Mononuclear infiltrates mainly lymphocytes were largely aggregated around blood vasculature in spleen of garlic-exposed embryos (Figure 6B). Furthermore, the splenic capsules were sharply destructed, and blood vessels showed profound areas of hemorrhage and congestion (Figure 6C). In some garlic-exposed embryos, splenic cells afford atrophy and lysis (Figure 6D). Histological examinations of ovary of the control pregnant rats showed normal ovarian structure comprising normal corpus luteum and normal development of the secondary follicles (Figure 7A). In the contrast, there was cystic ovary (Figure 7B), congestion of the ovarian vessels, and perivascular inflammation in garlic-treated pregnant rats (Figure 7C and D).



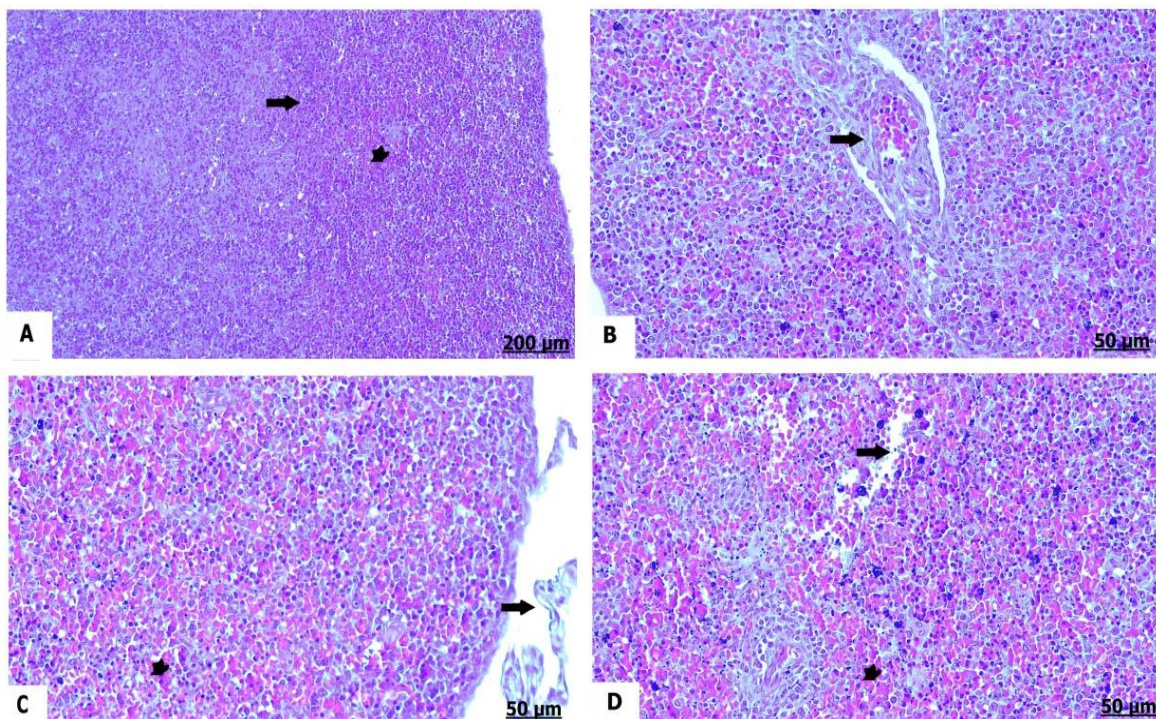
**Figure 3:** Photomicrograph of liver sections (hematoxylin and eosin stain) of pregnant female rats of the control group (A) and garlic-treated group (B, C, and D). (A) Healthy hepatic cords. (B) Fatty infiltration of the hepatocytes (arrow), besides mononuclear cells infiltrates (star). (C) Severely congested and dilated blood vessels (arrow). (D) Perivascular infiltration (arrow).



**Figure 4:** Photomicrograph of liver sections (hematoxylin and eosin stain) of embryo of the control group (A) and garlic-treated group (B, C, and D). (A) Showing normal hepatocytes. (B) Congestion of the blood vessels (arrow), besides focal aggregation of inflammatory cells (star). (C) Severely congested blood vessels and vacuolated hepatocytes (star). (D) Hepatocytes vacuolation with fatty infiltration (arrow).

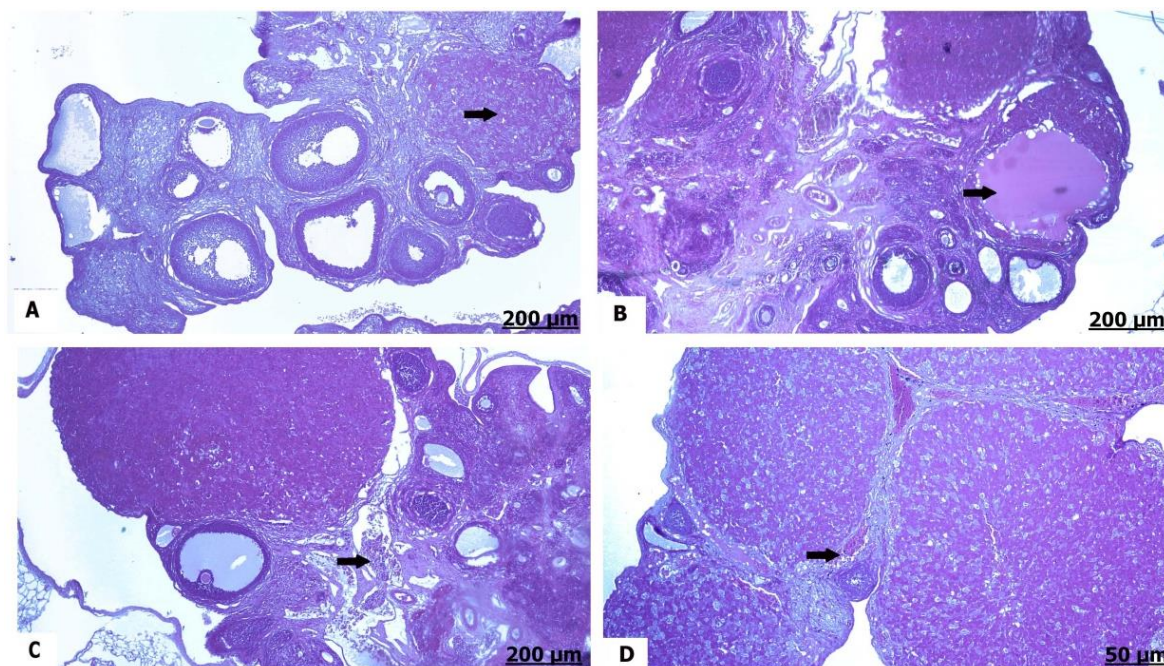


**Figure 5:** Photomicrograph of spleen sections (hematoxylin and eosin stain) of pregnant female rats of the control group (A) and garlic-treated group (B, C, and D). (A) Intact white pulps (arrow), in addition to normal red pulps (star). (B) Prominent congestion of the splenic arteries (arrow). (C) Remarkable protrusion of the splenic trabeculae (arrow). (D) Atrophied with vacuolated splenic tissues (arrow).



**Figure 6:** Photomicrograph of spleen sections (hematoxylin and eosin stain) of embryo of the control group (A) and garlic-treated group (B, C and D). (A) Intact red pulps (star), besides healthy white pulps (arrow). (B) Perivascular infiltrates (arrow). (C) Destruction of the splenic capsules (arrow), also hemorrhage and congestion of the red pulps. (D) Atrophy and lysis of splenic tissues (arrow).





**Figure 7:** Photomicrograph of ovary sections (hematoxylin and eosin stain) of pregnant female rats of the control group (A) and garlic-treated group (B, C and D). (A) Normal corpus luteum (arrow) and developing follicles. (B) Cystic ovary (arrow). (C and D) Congested blood vessels with perivascular lymphocytes infiltration (arrow).

Examination of liver sections of the control pregnant female showed absent collagen fibers infiltration (Figure 8A). Treatment by garlic denoted significant deposition of thick collagen fibers (Figure 8B, C, and D). Examination of liver sections of the control embryos manifested minimally distributed collagen fibers (Figure 9A). Liver of garlic-exposed embryos showed well developed hepatic fibrosis (Figure 9 B, C, & D).

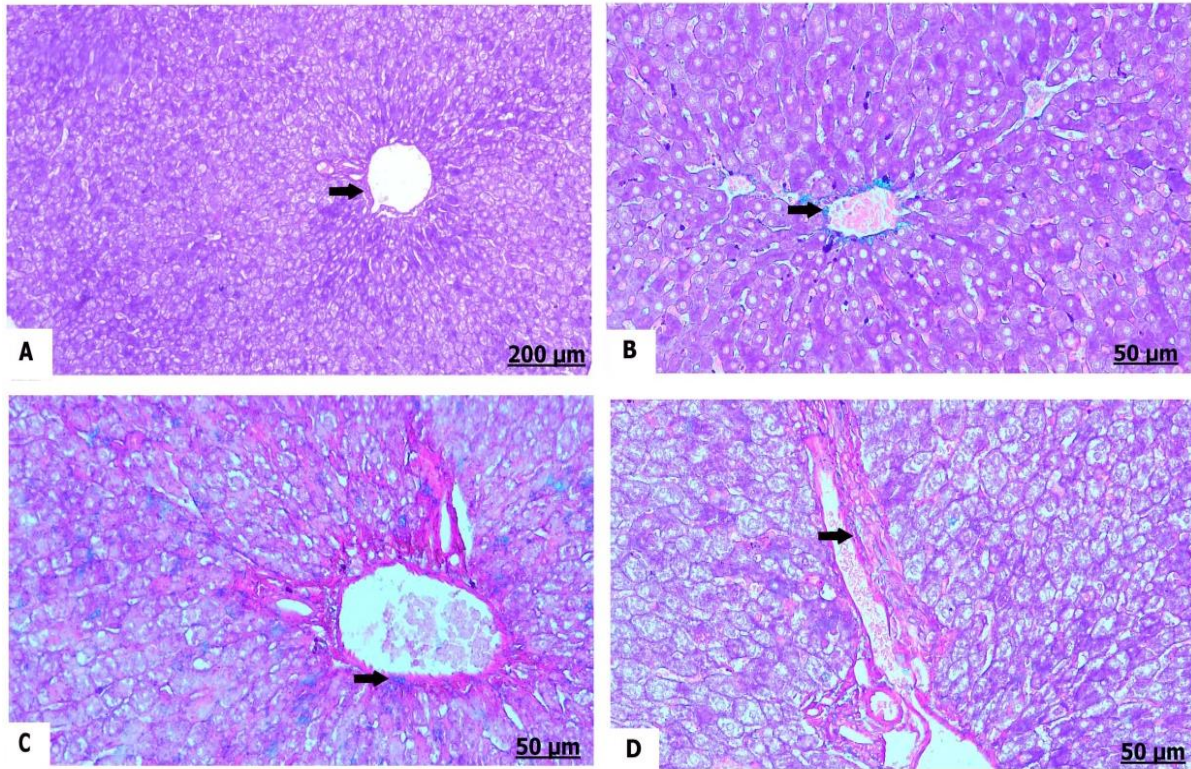
Examination of spleen sections of the control pregnant rats revealed less detectable collagen fibers (Figure 10A). The pregnant female which consumed garlic afforded severe replacement of the splenic parenchyma by thick areas of collagen fibers inside parenchyma (Figure 10 B, C, & D). In parallel of the control female rats, the control fetus exhibited normal arrangement of collagen fibers (Figure 11A). However, extensive fibrosis characterized by deep fibrous tissues formation was detected among garlic-exposed embryos (Figure 11B, C, and D).

Examination of ovarian sections of the control pregnant rats offered ovarian

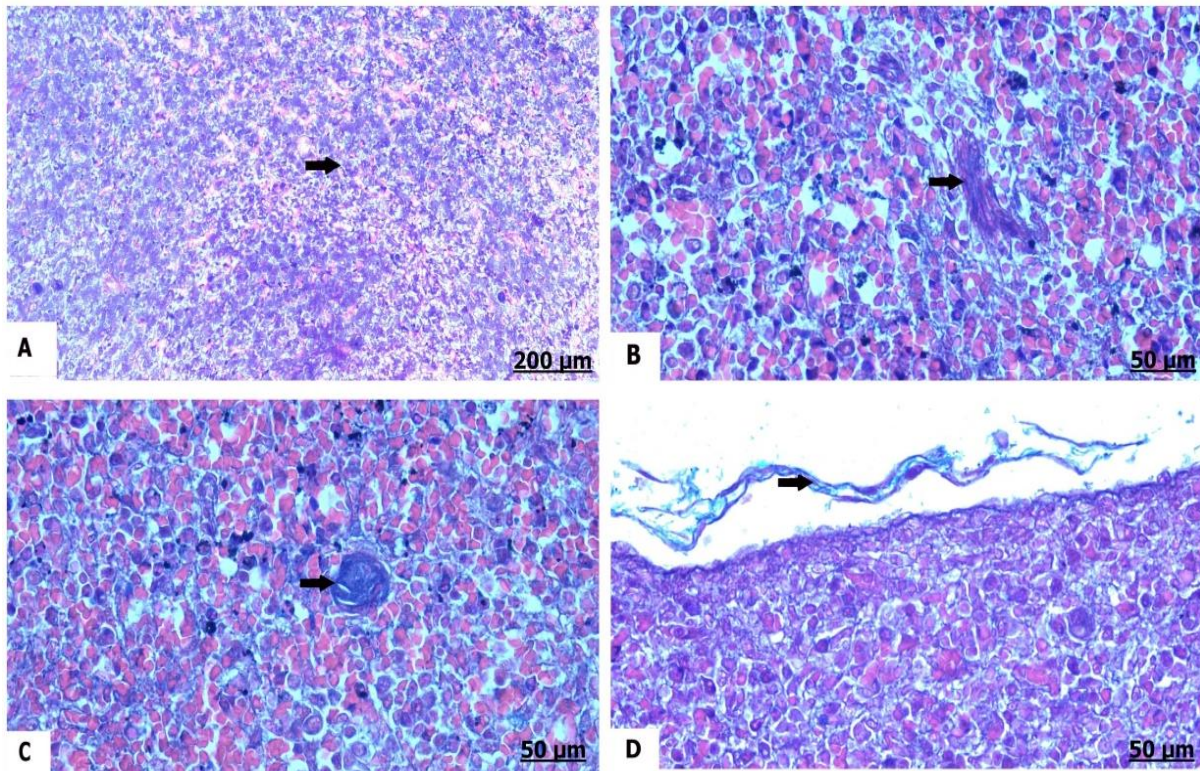
parenchyma containing less collagen fibers (Figure 12A). The ovary of garlic-treated pregnant female indicated marked perivascular fibrosis differentiated by sharp increase in collagen fibers around the ovarian vasculature (Figure 12B, C, and D).

## DISCUSSION

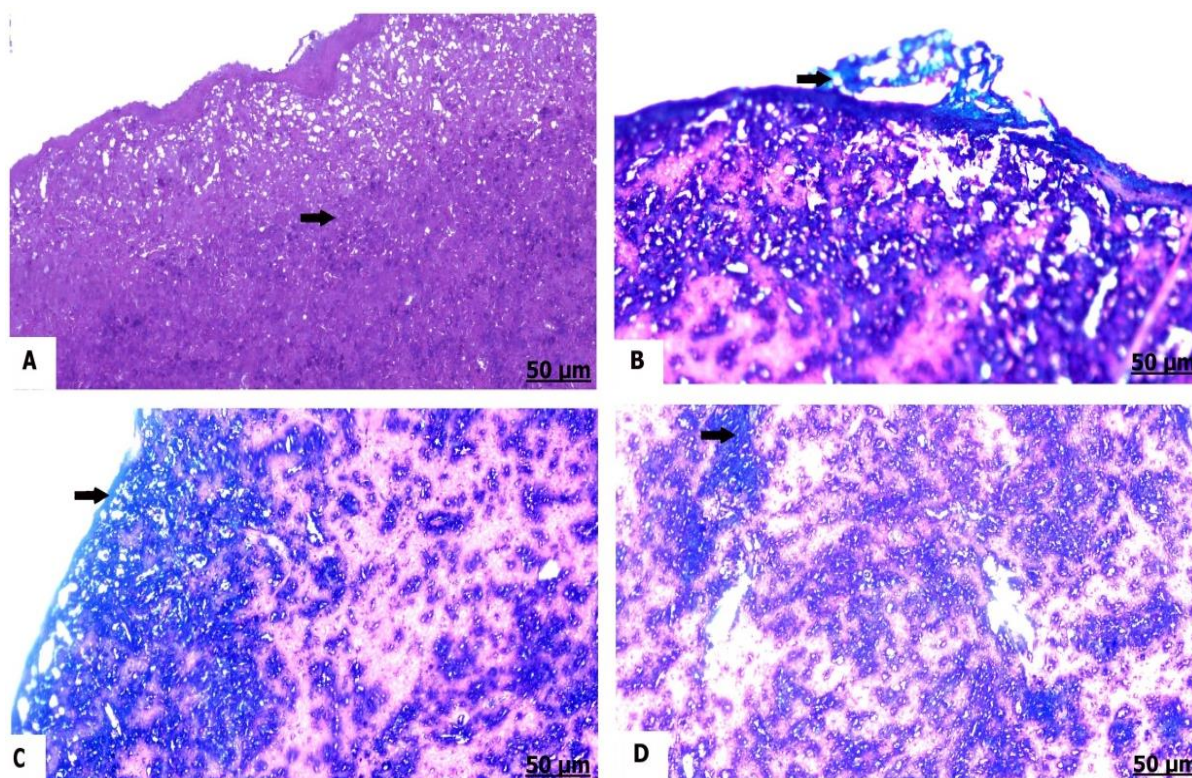
Natural products of plants, animals, and microbial origin have been lately utilized for thousands of years either in the pure forms or crude extracts to fight infectious diseases<sup>[26]</sup>. In developing countries, overwhelming interest was devoted to natural agents and plant products by using medicinal herbs to overlay their primary health care needs<sup>[27]</sup>. Garlic is one of the known medicinal plants, which previously used for treatment of diverse diseased conditions. The main benefit of garlic is owing to a higher concentration of sulfur and lavoura compounds, which are responsible for its medicinal values. Moreover, garlic of its broad-spectrum therapeutic activity with lowered toxicity responsible for management of various genera of fungi, bacteria, and viruses<sup>[26]</sup>. However, the usage of



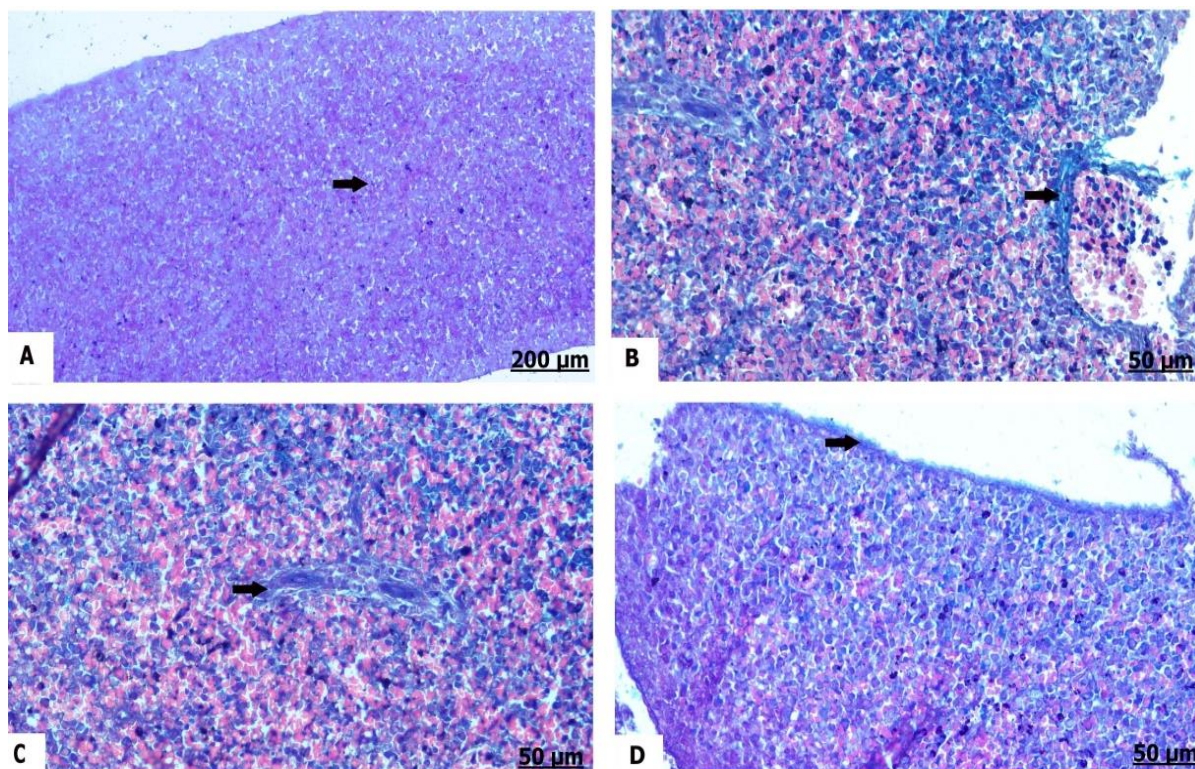
**Figure 8:** Photomicrograph of liver sections (Masson's trichrome stain) of pregnant female rats of the control group (A) and garlic-treated group (B, C and D). (A) Normally distributed collagen fibers (arrow). (B, C, and D) Deeply infiltrated collagen fibers (arrow).



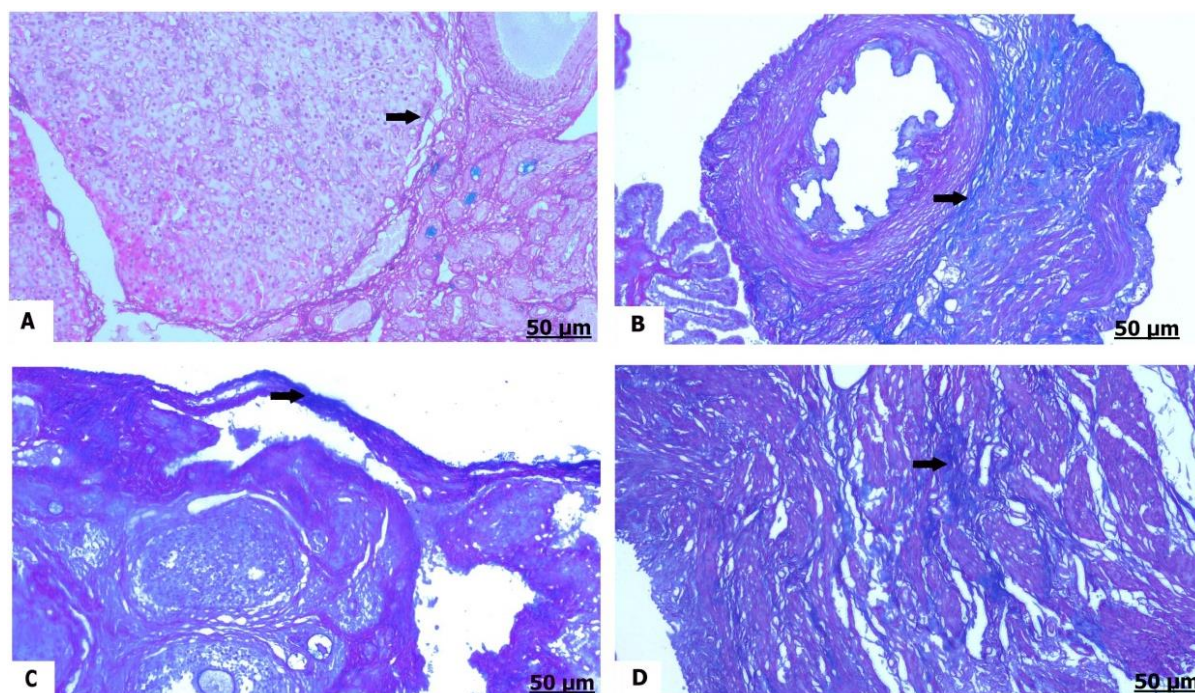
**Figure 9:** Photomicrograph of liver section (Masson's trichrome stain) of embryo of the control group (A) and garlic-treated group (B, C and D). (A) Less infiltration of the collagen fibers (arrow). (B, C, and D) More detectable collagen fibers (arrow).



**Figure 10.** Photomicrograph of spleen section (Masson's trichrome stain) of pregnant female rats of the control group (A) and garlic-treated group (B, C and D). (A) Collagen fibers distributed in a good manner (arrow). (B, C, and D) Significant deposition of collagen fibers (arrow).



**Figure 11:** Photomicrograph of spleen section (Masson's trichrome stain) of embryo of the control group (A) and garlic-treated group (B, C and D). (A) Normal distribution of the collagen fibers (arrow). (B, C, and D) Prominent perivascular collagen fibers (arrow).



**Figure 12:** Photomicrograph of ovary section (Masson's trichrome stain) of embryo of the control group (A) and garlic-treated group (B, C and D). (A) Normal distribution of the collagen fibers (arrow). (B, C, and D) More collagen fibers infiltration (arrow).

medicinal remedies should be based on scientific support; otherwise, they would become unsafe and useless. Furthermore, the illogical use of these natural products may bring serious toxicity for humanity. Unfortunately, a lot of people underrate the toxicity of herbals and do not understand that these products could be more toxic than synthetic drugs<sup>[28]</sup>. Correspondingly, safety of garlic evaluated at low concentrations. They suggested that garlic exerts some health benefits; but at higher levels, garlic may excite non-desirable effects<sup>[29]</sup>. In our data, total fetal body weights were reduced in-between embryos of garlic received pregnant female. Prolonged consumption of raw garlic is associated with weight loss, as result of subsequent anemia and the hemolytic lysis of erythrocytes<sup>[30]</sup>. Garlic oil diminished significantly the body weight gain of rats<sup>[31]</sup>. The possible interpretation for garlic toxicity is due to the sulfoxides present in garlic extract, which play an important role in exchange reactions with -SH groups of enzymes and other proteins, so inhibiting their activity<sup>[32]</sup>. Alliin and alliinase enzyme are the most active

constituents presented in *A. sativum* and are responsible for the toxicity of the bulb, since they liberated when fresh garlic bulb is grounded or chewed<sup>[33]</sup>. These compounds could also be responsible for the therapeutic and toxic virtues of the bulb.

Evaluation of serum biochemical biomarkers is the most beneficial tools for monitoring the general health status, functionality and integrity of organs, as well pathological condition of the body. Accordingly, serum ASAT and ALAT activities are hepatic integrity biomarkers, can be used to assure the extent of hepatocellular damage<sup>[34]</sup>. However, Serum ALAT activity that increased significantly in garlic-treated pregnant rats provided more worthy information found of the integrity of the hepatocyte than ASAT<sup>[35]</sup>. Consequently, in the present study, serum levels of total protein was significantly increased in garlic-treated rats when compared with the control rats. The garlic extract induced selective changes in some biochemical indices of organ function at a dose of 300 mg/kg<sup>[36]</sup>. It have been shown that higher doses of garlic powder lead to

considerable hepatic injury in rats, which doesn't notice at lower doses<sup>[37]</sup>. According to the research-based investigations, excessive garlic ingestion in particular of raw garlic<sup>[38]</sup> may provoke hepatotoxicity by dint of consequent elevation the activity of liver enzymes<sup>[9]</sup>; besides this, garlic possesses a cytotoxic effect on other tissues, leading to cruel damaging effect. Additionally, garlic attended an increment in the activity of ALP and lactate dehydrogenase activities in the serum of rats<sup>[39]</sup>.

Oxidative stress is an imbalance between the free radicals synthesis and the ability of the cells to neutralize extremely reactive intermediates resulting damage<sup>[40]</sup>. In any biological system, oxidative stress take places as a consequence of increases production of reactive oxygen species and the direct depletion of antioxidant reserves<sup>[41]</sup>. MDA is a naturally occurring reactive compound as an indicator for oxidative stress<sup>[42]</sup>. SOD and GPx are enzymatic antioxidants endogenously produced in the cells<sup>[43]</sup>. Under normal physiological conditions, the content of antioxidants is actually appropriate to the generated free radicals at a normal physiological range. Any subsequent increase in the level of free radicals due to some causes can develop an imbalance between the free radicals and antioxidants reserves create oxidative stress<sup>[44]</sup>. Hence, our data demonstrated a significant increment in serum IL-6, MDA, and nitric oxide, contrary to a significant decrease in serum SOD and GPx activities. Garlic powder altered and hampered the formation of superoxide at IC<sub>50</sub> of 390 µm/mL, where sulfur constituents of garlic are mainly responsible for conveying the antioxidative characters of garlic<sup>[45]</sup>. However, elevated garlic concentration has the potential ability to altered significantly the endogenous antioxidants system (catalase and SOD)<sup>[9]</sup>. Besides this, *Allium sativum* had immunomodulatory effect with consequent suppression of inflammatory cytokines<sup>[11]</sup>.

Herein, histological findings of garlic-treated pregnant rats showed pronounced

hepatic vacuolation, besides severe congestion of the blood vessels. Since, fresh garlic preparation exhibited various morphological changes such as swelling of the liver and hypertrophied spleen after 3 and 8 days post-exposure<sup>[46]</sup>. Approximately 1000 mg/kg/day of garlic caused marked histopathological changes in liver. These changes in liver were characterized by focal areas of necrosis with inflammatory cells infiltration and hemorrhage<sup>[9]</sup>. As well as, ingestion of 3200 and 4200 mg/kg of garlic aqueous extract induced slight congestion of liver<sup>[47]</sup>. Intraperitoneal therapy of 500 mg/kg/day of garlic extracts resulted in more detectable tissues damaging with profound morphological alterations in liver of the exposed rats<sup>[29]</sup>. Moreover, rats administrated 300 and 600 mg/kg of garlic aqueous extract for 21 days resulted in toxic effects on body weight, development biological parameters, and histological screening<sup>[48]</sup>. On the other hand, non-significant gross necropsy and microscopic changes were observed in liver and spleen of Sprague Dawleys' rats administered varying doses of garlic ethyl acetate extract of 300, 2000, and 5000 mg/kg of body weight<sup>[49]</sup>.

In spleen of garlic-treated pregnant rats, we found atrophy and vacuolation of splenic pulps. The higher concentrations of garlic extract leading to a significant alteration of the splenic tissues distinguished with damaging effect to the white pulp<sup>[50]</sup>. An excess dose of garlic was associated with some gastrointestinal problems and anemia issues<sup>[7]</sup>. The use of garlic during pregnancy has been associated with a variety of adverse embryonic outcome in the form of premature death and fetal weights retardation. Ingestion of pregnant female to 1.5 g of garlic once daily exhibited clinical manifestations that was typically responsible for maternal colic<sup>[51]</sup>. Moreover, garlic juice induced chromosomal damage resulted in significant inhibition of cellular growth and retard cell differentiation<sup>[52]</sup>.

In conclusion, according to the based findings which previously discussed, garlic

produced significantly cytotoxicity in liver, spleen, and ovary of the pregnant rats and their progeny and crucially incited congenital retardation in the development of fetuses. Biochemical and histological examinations signify that garlic proceeds *via* cell degeneration and fibrosis.

#### FUNDING SOURCE DISCLOSURE

This study received no specific grant from any funding agency in public, commercial, or not-for-profit sectors.

#### CONFLICT OF INTEREST

The authors declare no conflict of interest.

#### REFERENCES

- [1] Doughari, J. H. (2012). Phytochemicals: Extraction Methods, Basic Structures and Mode of Action as Potential Chemotherapeutic Agents. In: *Phytochemicals - A Global Perspective of Their Role in Nutrition and Health* (Rao, V. ed), pp. 1-32. InTechOpen, London, UK.
- [2] Heinrich, M.; Bames, J.; Gibbons, S. *et al.* (2004). *Fundamentals of Pharmacognosy and Phytotherapy*. Churchill Livingstone, London, UK.
- [3] Tattelman, E. (2005). Health effects of garlic. *Am Fam Physician*, 72:103-106.
- [4] Sarker, S. D. and Nahar, L. (2007). *Chemistry for Pharmacy Students*. John Wiley & Sons Ltd., Hoboken, NJ, USA.
- [5] Hamlaoui-Gasmi, S.; Mokni, M.; Limam, N. *et al.* (2011). Effect of the route of garlic treatment on modulation of liver and spleen redox status in rats. *J Med Plants Res*, 5(15): 3466-3474.
- [6] Fowotade, A. A.; Fowotade, A.; Enaibe, B *et al.* (2017). Evaluating toxicity profile of garlic (*Allium sativum*) on the liver, kidney and heart using Wistar rat model. *IJTDH*, 26(2): 1-12.
- [7] Banerjee, S. K.; Mukherjee, P. K. and Maulik, S. K. (2003). Garlic as an antioxidant: the good, the bad and the ugly. *Phytother Res*, 17(2): 97-106.
- [8] Egen-Schwind, C.; Eckard, R. and Kemper, F. H. (1992). Metabolism of garlic constituents in the isolated perfused rat liver. *Planta med*, 58(4): 301-305.
- [9] Banerjee, S. K.; Maulik, M.; Manchanda, S. C. *et al.* (2001). Garlic-induced alteration in rat liver and kidney morphology and associated changes in endogenous antioxidant status. *Food Chem Toxicol*, 39(8): 793-797.
- [10] Al-Salahy, M. B. and Mahmoud, A. B. (2003). Metabolic and histological studies on the effect of garlic administration on the carnivorous fish *Chrysichthys auratus*. *Egypt J Biol*, 5: 94-107.
- [11] Kyo, E.; Uda, N.; Kasuga, S. *et al.* (2001). Immunomodulatory effects of aged garlic extract. *J Nutr*, 131(3s): 1075S-1079S.
- [12] Bronte, V. and Pittet, M. J. (2013). The spleen in local and systemic regulation of immunity. *Immunity*, 39(5): 806-818.
- [13] Kodera, Y.; Suzuki, A.; Imada, O. *et al.* (2002). Physical, chemical, and biological properties of S-allylcysteine, an amino acid derived from garlic. *J Agric Food Chem*, 50(3): 622-632.
- [14] Amer, N.; Khuder, M. H.; Yacoub, S. A. *et al.* (2013). Histological effects of excessive consumption of *Zingiber officinale* on liver and spleen of the mice. *ANJS*, 16(2): 151-156.
- [15] Balbontín, Y. M.; Stewart, D.; Shetty, A. *et al.* (2019). Herbal medicinal product use during pregnancy and the postnatal period: a systematic review. *Obstet Gynecol*, 133(5): 920-932.
- [16] Wadaan, M. A. M. (2009). Long-term effects of black seed and garlic oil on the offspring of two consecutive pregnancies in rats. *J King Saud Univ Sci*, 21(3): 155-161.
- [17] Gatsing, D.; Aliyu, R. and Meli, W. B. (2003). Phytochemical profile and

- antisalmonellal properties of *Allium sativum* bulb extract. West African Journal of Biological Sciences, 14: 29-36.
- [18] Nishikawa-Ogawa, M.; Wanibuchi, H.; Morimura, K. *et al.* (2006). N-acetylcysteine and S-methylcysteine inhibit MeIQx rat hepatocarcinogenesis in the post-initiation stage. *Carcinogenesis*, 27(5): 982-988.
- [19] Reitman, S. and Frankel, S. (1957). A colorimetric method for the determination of serum glutamic oxalacetic and glutamic pyruvic transaminases. *Am J Clin Pathol*, 28: 56-63.
- [20] Gornall, A. G.; Bardawill, C. J. and David, M. M. (1949). Determination of serum proteins by means of the biuret reaction. *J Biol Chem*, 177(2): 751-766.
- [21] Ohkawa, H.; Ohishi, N. and Yagi, K. (1979). Assay for lipid peroxides in animal tissues by thiobarbituric acid reaction. *Anal biochem*, 95(2): 351-358.
- [22] Rider, B. F. and Mellon, M. G. (1946). Colorimetric determination of nitrites. *Ind Eng Chem Anal Ed*, 18(2): 96-99.
- [23] Nishikimi, M.; Appaji, N. and Yagi, K. (1972). The occurrence of superoxide anion in the reaction of reduced phenazine methosulfate and molecular oxygen. *Biochem Biophys Res Commun*, 46(2): 849-854.
- [24] Paglia, D. E. and Valentine, W. N. (1967). Studies on the quantitative and qualitative characterization of erythrocyte glutathione peroxidase. *J Lab Clin Med*, 70: 158-169.
- [25] Carleton, H. M.; Drury, R. A. B. and Wallington, E. A. (1980). *Carleton's Histological Technique*. Oxford University Press, Oxford, UK.
- [26] Parekh, J. and Chanda, S. (2007). *In vitro* antimicrobial activity of *Trapa natans* L. fruit rind extracted in different solvents. *Afr J Biotechnol*, 6(6): 766-770.
- [27] WHO (2002). *Traditional Medicine: Growing Needs and Potential* (WHO/EDM/2002.4). World Health Organization (<https://apps.who.int/iris/handle/10665/67294>).
- [28] Tripathi, K. D. (2013). *Essentials of Medical Pharmacology*. JP Medical Ltd, London, UK.
- [29] Yadav, R. K. and Verma, N. S. (2004). Effects of garlic (*Allium sativum*) extract on the heart rate, rhythm and force of contraction in frog: a dose-dependent study. *Indian J Exp Biol*, 42(6): 628-631.
- [30] Augusti, K. T. (1996). Therapeutic values of onion (*Allium cepa* L.) and garlic (*Allium sativum* L.). *Indian J Exp Biol*, 34(7): 634-640.
- [31] Sheen, L. Y.; Chen, H. W.; Kung, Y. L. *et al.* (1999). Effects of garlic oil and its organosulfur compounds on the activities of hepatic drug-metabolizing and antioxidant enzymes in rats fed high-and low-fat diets. *Nutr cancer*, 35(2): 160-166.
- [32] Banerjee, S. K. and Maulik, S. K. (2002). Effect of garlic on cardiovascular disorders: a review. *Nutr J*, 1: 4 (DOI: 10.1186/1475-2891-1-4).
- [33] Rahman, M. M.; Fazlic, V. and Saad, N. W. (2012). Antioxidant properties of raw garlic (*Allium sativum*) extract. *Int Food Res J*, 19(2): 589-591.
- [34] Shittu, O. K.; Lawal, B.; Haruna, G. M. *et al.* (2015). Hepato-curative effects of methanol extract from Nigerian bee propolis in carbon tetrachloride (CCl<sub>4</sub>) intoxicated rats. *European J Biotechnol Biosci*, 3(7): 1-4.
- [35] Lawal, B.; Shittu, O. K.; Abubakar, A. N. *et al.* (2015). Evaluation in Wister Rats (*Rattus Novergicus*) following chronic exposure of methanol leaf extract of *Telfairia occidentalis*. *J Pharm Biomed Sci*, 05(09): 740-744.
- [36] Lawal, B.; Shittu, O. K.; Oibiokpa, F. I. *et al.* (2016). Antimicrobial

- evaluation, acute and sub-acute toxicity studies of *Allium sativum*. J Acute Dis, 5(4): 296-301.
- [37] Rana, S. V.; Pal, R.; Vaiphei, K. *et al.* (2011). Garlic in health and disease. Nutr Res Rev, 24, 60-71.
- [38] Olaiya, O. G.; Ailenosi, S. S.; Adelaja, A. *et al.* (2011). Effects of aqueous extract of garlic and vitamin C on the kidney of albino rats. Asian J Exp Biol Sci, 2(3): 455-61.
- [39] Omotoso, G. O.; Muonagolu, J. N. and Enaibe, B. U. (2012). Histological evaluation of the jejunum and ileum of rats after administration of high dose garlic aqueous extract. Int J Health Sci (Qassim), 6(2): 135-140.
- [40] Patra, R. C.; Rautray, A. K. and Swarup, D. (2011). Oxidative stress in lead and cadmium toxicity and its amelioration. Vet Med Int, 2011: 457327 (DOI: 10.4061/2011/457327).
- [41] Ercal, N.; Gurer-Orhan, H. and Aykin-Burns, N. (2001). Toxic metals and oxidative stress part I: mechanisms involved in metal-induced oxidative damage. Curr Top Med Chem, 1(6): 529-539.
- [42] Yang, R.-L.; Shi, Y.-H.; Hao, G. *et al.* (2008). Increasing oxidative stress with progressive hyperlipidemia in human: relation between malondialdehyde and atherogenic index. J Clin Biochem Nutr, 43(3): 154-158.
- [43] Flora, S. J. S. (2009). Structural, chemical and biological aspects of antioxidants for strategies against metal and metalloid exposure. Oxid Med Cell Longev, 2(4): 191-206.
- [44] Blokhina, O.; Virolainen, E. and Fagerstedt, K. V. (2003). Antioxidants, oxidative damage and oxygen deprivation stress: a review. Ann bot, 91(2): 179-194.
- [45] Siegers, C. P.; Röbbke, A. and Pentz, R. (1999). Effects of garlic preparations on superoxide production by phorbol ester activated granulocytes. Phytomedicine, 6(1): 13-16.
- [46] Chen, L.; Hong, J. Y.; So, E. *et al.* (1999). Decrease of hepatic catalase level by treatment with diallyl sulfide and garlic homogenates in rats and mice. J Biochem Mol Toxicol, 13(3-4): 127-134.
- [47] Mikail, H. G. (2010). Phytochemical screening, elemental analysis and acute toxicity of aqueous extract of *Allium sativum* L. bulbs in experimental rabbits. J Med Plant Res, 4(4): 322-326.
- [48] Fehri, B.; Aiache, J. M.; Korbi, S. *et al.* (1991). Toxic effects induced by the repeat administration of *Allium sativum* L. J Pharm Belg, 46(6): 363-374.
- [49] Njue, L. G.; Ombui, J. N.; Kanja, L. W. *et al.* (2015). Evaluation of oral toxicity level of ethyl acetate extract, from garlic (*Allium sativum*) in onorrh dawleys rats as per OECD guidelines 423. J Food Sci Technol, 2(3): 056-064.
- [50] Andrew, U. O.; Ozoko, L. E. C.; Kingsley, I. A. *et al.* (2017). Histologic effect of garlic extract on the spleen of adult wistar rat. IOSR-JPBS, 12: 1-4.
- [51] Mennella, J. A. and Beauchamp, G. K. (1993). The effects of repeated exposure to garlic-flavored milk on the nursling's behavior. Pediatr Res, 34(6): 805-808.
- [52] Charles, G. D.; Linscombe, V. A.; Tornesi, B. *et al.* (2002). An *in vitro* screening paradigm for extracts of whole foods for detection of potential toxicants. Food Chem Toxicol, 40(10): 1391-1402.

**How to cite this article:**

Kamal, Z.; Al-Amgad, Z. and Mobarak, S. A. (2024). The relationship between aggravated *Allium sativum* consumption and cytotoxicity of the pregnant rats with subsequent embryonic growth retardation. Egyptian Journal of Zoology, 81: 44-60 (DOI: 10.21608/ejz.2023.218674.1098).



## العلاقة بين الاستهلاك الزائد للثوم (*Allium sativum*) وتسمم الخلايا في الجرذان الحوامل وما يترتب عليه من تأخر النمو الجنيني

زينب كمال<sup>1</sup>، زينب الأمجد<sup>2</sup>، سهام علي مبارك<sup>1</sup>

<sup>1</sup>قسم علم الحيوان، كلية العلوم، جامعة جنوب الوادي، قنا، جمهورية مصر العربية  
<sup>2</sup>الهيئة العامة للخدمات البيطرية، مديرية الطب البيطري بقنا، جمهورية مصر العربية

تستخدم الأعشاب والتوابل بكثرة في الطعام والأغراض الطبية. ويعتبر الثوم (*Allium sativum*) أحد أكثر الأعشاب المستخدمة في الأنظمة الغذائية والعلاجية، خصوصا في الدول النامية، رغم وجود جدل حول التأثيرات المفيدة أو السامة التي تعتمد على جرعة الثوم وطريقة تناوله. تم توزيع 20 جرّدًا من الإناث الحوامل بالتساوي إلى مجموعتين: المجموعة الضابطة والمجموعة المعاملة بالثوم (ن = 10). في المجموعة المعاملة بالثوم، تم إعطاء كل جرّد حامل عن طريق الفم "2 جم/كجم من وزن الجسم" من مستخلص الثوم المائي في اليوم السادس من الحمل. وفي اليوم العشرين من الحمل تم إجراء الفحوصات المورفولوجية والكيميائية الحيوية والنسجية لتقدير التشوهات الخلوية في مبيض الأم، والأضرار التي لحقت بالكبد والطحال لكل من الجرذان الحوامل وأجنحتها. وقد أظهرت النتائج أن المعاملة بمستخلص الثوم (2 جم/كجم من وزن الجسم) أدت إلى حدوث تسمم خلوي شديد لأنسجة الكبد والطحال للأمهات وأجنحتها، وتشوهات خلقيّة واضحة في الأجنة. وأظهرت النتائج ارتفاع ذو دلالة إحصائية في نشاط إنزيم الأسبرتات أمينوترانسفيريز، ومستويات البروتين الكلي، والإنترلوكين-6، والمالوندايديهايد، وأكسيد النيتريك، بينما وُجد انخفاض ذو دلالة إحصائية في أنشطة إنزيمات السوبر أوكسيد ديسموتيز والجلوتاثيون بيروكسيديز في المجموعة المعاملة بالثوم عند مقارنتها بالمجموعة الضابطة. الخلاصة: أظهر مستخلص الثوم المائي خللاً ذو دلالة إحصائية في وظائف الكبد ومناعة الجرذان الحوامل، بالإضافة إلى تشوهات خلقيّة في الأجنة.